

# EFFECT OF MERCURIC CHLORIDE ON THE OVARY OF FRESHWATER CRAB *BARYTELPHUSA CUNICULARIS*

F. I. SHAIKH<sup>1\*</sup>, I. R. USTAD AND N. T. ANSARI

<sup>1</sup>Department of Zoology, Milliya College, Beed - 431 122

Department of Zoology, Sir Sayyed College, Aurangabad - 430 001

E-mail: drshaikhferoz1974@gmail.com

## KEY WORDS

Mercuric chloride  
Ovary, Histopathology  
*Barytelphusa cunicularis*

## Received on :

07.01.2010

## Accepted on :

19.04.2010

\*Corresponding  
author

## ABSTRACT

The effect of mercuric chloride on the histopathology of ovary showed pycnosis of nutritive cells and shrinkage of oocyte. Destruction of epithelial layer and degeneration of oocytes was found. The epidermal layer was loosely arranged. Vacuolization was also observed in the periphery of the oocyte cells during acute and chronic treatment.

## INTRODUCTION

Many heavy metals are known for their strong action towards biological tissues into which they are bioaccumulated if absorbed into the body of an organism. The metal ions cause damage to the cells and the tissues in varying degrees depending upon their toxic phenomenon.

The histopathological studies not only give an early indication of pollution hazard, but also provide useful data on nature and degree of damage to cells and tissues. It is a common tool for determining the deleterious effects of toxic substances in animals. Many workers have employed this tool in the study of aquatic pollution. Vernberg and Vernberg (1972) have observed changes in the gill tissue of crab after exposure to sublethal concentration of mercury. Ghate and Mulherkar (1979) have studied the changes in the gill tissue of two freshwater prawns *Macrobrachium lamerrii* and *Caridina weberi* exposed to copper sulphate. Bodkhe (1983) reported the histopathological changes in the gills of freshwater crab, *Barytelphusa cunicularis*.

Due to the accumulation of the pollutant in aquatic ecosystem the reproductive process gets decelerated and on the other hand long term exposure to the pollutant causes a considerable damage to the tissues of reproductive organ decelerating the reproductive cycle and restricting the development of eggs. Hatching of the eggs and newly hatched young ones are also affected by the exposure to the pollutants and ultimately reduces their long term exposure more pollutants gets accumulated in the tissue of the animal and thus it becomes unfit for human use.

Subhas (1988) observed the effect of benzene on changes in gonadal structure of marine crab *Scylla serrata*.

In the present investigation the effect of heavy metal is studied on the ovary of freshwater crab, *Braytelphusa cunicularis* after lethal and sublethal exposure.

## MATERIALS AND METHODS

The freshwater crab, *Braytelphusa cunicularis* were collected from Godavari River at Paithan near Aurnagabad. The crabs were acclimatized to laboratory conditions for about 2 to 3 days in a plastic trough containing 2L of tap water before being used for the experiment. Selected healthy animals were used for the experimental studies.

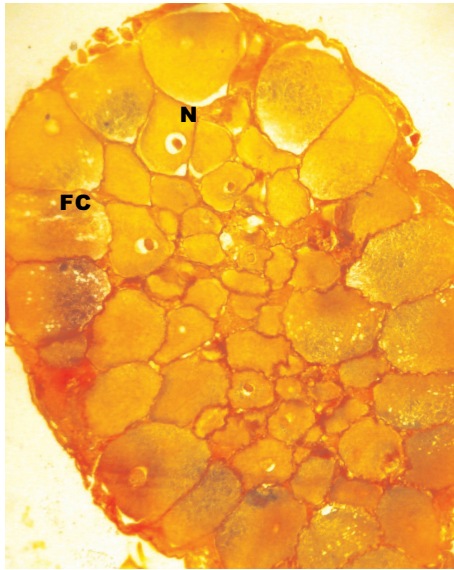
To study the histopathological lesions in the ovary, crabs were exposed to mercuric chloride at lethal and sublethal concentrations respectively, simultaneously control groups of crabs were also maintained as described elsewhere (Vernberg and Vernberg, 1972 )

At the end of the exposure period, the experimental and control crabs were sacrificed and the ovaries were quickly excised and fixed in Bouin's fixative. After fixation for 24 hrs the tissues were washed and dehydrated in graded series of alcohol and cleared in xylene. They were embedded in paraffin wax and serial section were cut ( 7-8 $\mu$  thick) and stained with Mallory triple stain ( Mallory, 1944).

## RESULTS

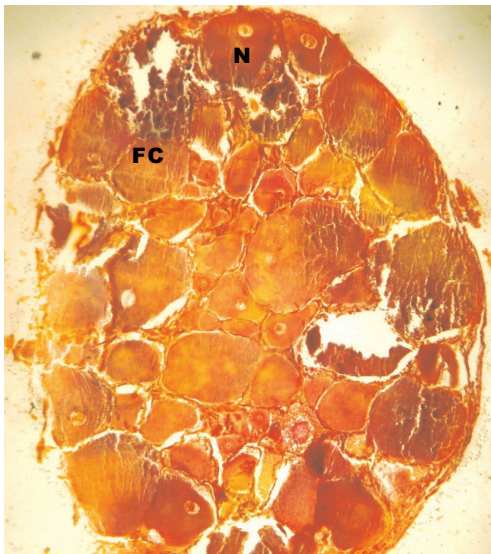
Histologically, ovaries of control crabs were covered with outer thin epithelium and inner germinative epithelial layer from which the oocytes proliferate. The mature oocyte is covered with these membranes i.e. oocyte membranes. Oocyte has a large rounded nucleus with one or two nucleoli. The nutritive

cells are present in the close vicinity of the oocyte. The oocytes are covered with a layer of follicle cell. The ooplasm is compactly arranged with thick yolk granules. Ovarian follicles are filled with different types of maturing oocytes (Fig. 1).



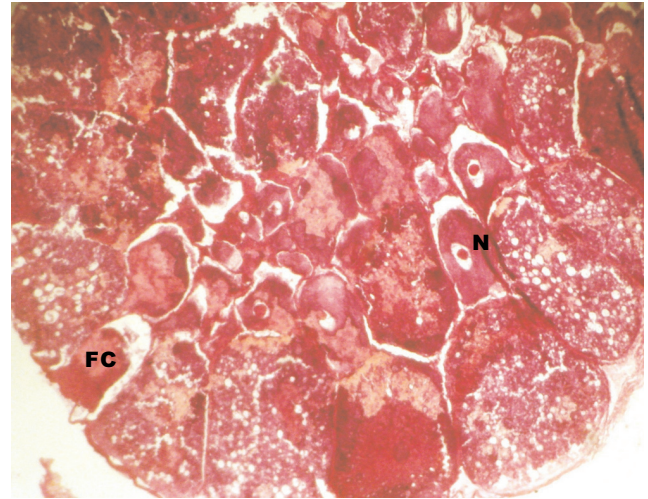
**Figure 1:** T. S. of ovary of control freshwater crab, *Barytelphusa cunicularis*; Mallory triple x 100; FC = Follicular cells; N = Nucleus

After 24 hrs of exposure pycnosis of nutritive cells and nucleus of oocyte was observed due to shrinkage of oocyte. Destruction of epithelial layer and degeneration of oocytes were seen, epidermal layer was loosely arranged, vacuolization was also observed in the periphery of the oocyte (Fig. 2).



**Figure 2:** T. S. of ovary of freshwater crab, *Barytelphusa cunicularis* exposed to mecuric chloride for 24 hrs.; Mallory triple x 100; FC = Follicular cells; N = Nucleus


In the ovary of 48 hrs exposure brought about damage to ovarian layer destruction of follicular epithelial layer and vacuolization towards the periphery of oocytes proliferation continues but no. vitellogenesis took place and increase in the no. of phagocytes, as ovary enters in degenerating phase, was



**Figure 3:** T. S. of ovary of freshwater crab, *Barytelphusa cunicularis* exposed to mecuric chloride for 48 hrs.; Mallory triple x 100; FC = Follicular cells; N = Nucleus

also noticed (Fig. 3).

After 72 hrs exposure ovary showed irregular shape of oocytes, mixing of ooplasmic material due to disintegration of follicular epithelium, maximum nature of degenerating oocytes with disintegrated nuclei was observed are more in peripheral region of lobules. Disappearance of nucleus in some oocytes was noticed (Fig. 4).



**Figure 4:** T. S. of ovary of freshwater crab, *Barytelphusa cunicularis* exposed to mecuric chloride for 72 hrs.; Mallory triple x 100; N = Nucleus

In case of 96 hrs exposure, mixing of ooplasmic material due to disintegration of follicular epithelium, fusion of three or four oocytes together and maximum no of degenerating oocytes with disintegrated nuclei were observed (Fig. 5).

After 10 days of exposure oocytes were found to be scattered, rupturing of epithelial layer of oocytes and vacuolisation in the oocytes were observed (Fig. 6).

After 20 days of exposure the degeneration of peripheral oocytes, shrinkage of ooplasmic material and increase in number of phagocytes within the ovarian stroma were



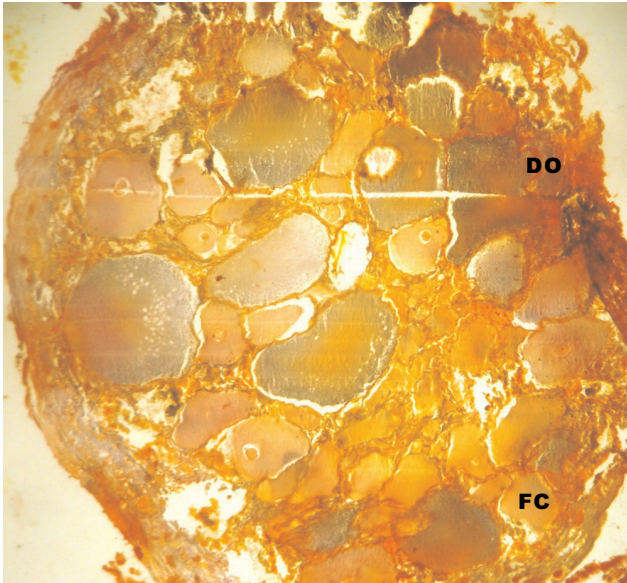


Figure 5: T. S. of ovary of freshwater crab, *Barytelphusa cunicularis* exposed to mecuric chloride for 96 hrs.; Mallory triple x 100; FC = Follicular cells; DO = Degenerating oocyte

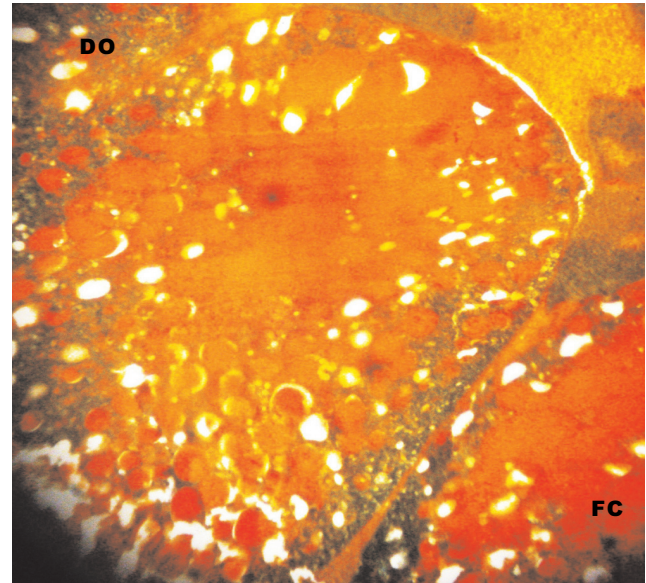


Figure 7: T. S. of ovary of freshwater crab, *Barytelphusa cunicularis* exposed to mecuric chloride for 20 days; Mallory triple x 100; FC = Follicular cells; DO = Degenerating oocyte

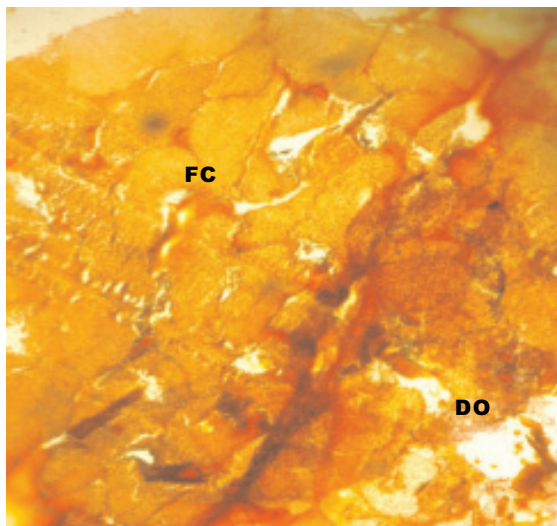


Figure 6: T. S. of ovary of freshwater crab, *Barytelphusa cunicularis* exposed to mecuric chloride for 10 days; Mallory triple x 100; FC = Follicular cells; DO = Degenerating oocyte

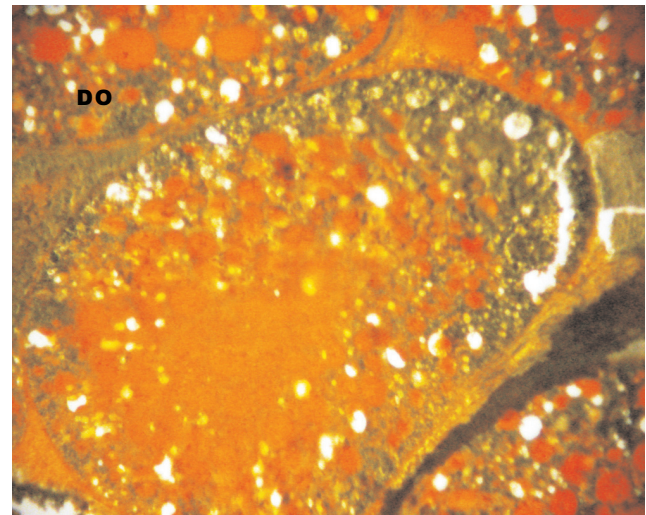


Figure 8: T. S. of ovary of freshwater crab, *Barytelphusa cunicularis* exposed to mecuric chloride for 30 days; Mallory triple x 100; DO = Degenerating oocyte

observed (Fig. 7).

In case of 30 days exposure complete damage to ovarian structure was observed, such as total damage in oocyte epithelial layer and vacuolization in the oocyte. The yolk granules and ft globules were observed in rich amount (Fig. 8).

## DISCUSSION

The accumulation of heavy metals within the organism body of lethal and sublethal levels leads to histological lesion in the body when accumulated in the reproductive organ. Acute and chronic exposure of mercuric chloride to *Barytelphusa cunicularis* causes several histological lesions in the ovary. The degeneration of oocyte followed by vacuolization in the ooplasm, destruction of membrane and shrinkage of ooplasm was observed after acute

and chronic exposure.

The present results are in agreement with the results of Gyananath (1982) and Reddy *et al.*, (1982) who observed the same effect the ovarian tissue of freshwater prawn, *Macrobrachium lamerrii* and *Caridina weberi* respectively, after exposure to pesticide.

Victor and Sarojini (1984) reported changes in the normal structure of the ovary in prawn, *Caridina rajadhari*. Machale *et al.*, (1990) studied that cuprous oxide exposure induced significant alternations in the ovary of the crab *Barytelphusa guerini*. Bhagylakshmi *et al.*, (1982) reported rupturing of oocyte, vacuolization, irregular arrangement of oocyte and disappearance of nucleus were observed in freshwater crab, *Barytelphusa cunicularis* during sublethal exposure of heavy metal.

## REFERENCES

- Bodkhe, M. K. 1983.** Effect of some pesticidal pollutant on the physiology of *Barytelphusa cunicularis*. Ph. D. Thesis Dr. B. A. M. U. Aurangabad.
- Ghate, H. V. Mulherkar 1979.** Histological changes in the gills of two freshwater prawn species exposed to copper sulphate. *Indian J. Expt. Biol.* **17(8)**: 838 – 840.
- Gyananath 1982.** Reproductive Biology of the freshwater prawn, *Macrobrachium lamerri*. Ph. D. Thesis Dr. B. A. M. U. Aurangabad.
- Machale, P. R., Sarojini, R., Khan, A. K. and Nagabhushanan, R. 1990.** Histological changes in the ovary of freshwater crab, *Barytelphusa guerini* exposed to cuprous oxide. *J. Inv. Zool. and Aqua. Biol.* **2(1)**: 55 – 58
- Mallory, F. 1944.** Pathological techniques, W. B. Saunders, Philadelphia.
- Reddy, S. L. N., Shankaraiah, K. and Raman Rao, K. V. 1982.** Time course alteration in protein metabolism of freshwater field crab, *Barytelphusa guerini*. In proceedings of the all India symposium on physiological responses of animals to pollutants, Dr. B. A. M. U. Aurangabad.
- Subhash, M. 1988.** Physiological responses of marine crab, *Scylla serrata* to petroleum hydrocarbon Ph. D. Thesis, Dr. B. A. M. U. Aurangabad.
- Vernberg, W. B. and Vernberg, F. J. 1972.** The synergistic effect of temperature salinity and mercury on survival and metabolism of the adult fiddler crab *Uca pugilator*. *Fish Bull.* **70**: 415 – 420.
- Victor, B. and Sarojini, R. 1986.** Toxicity of an organophosphate insecticide to the *Caridina rajadhari* (Bamiar). *J. Environ. Biol.* **7(1)**: 46 – 50.